



Journal homepage:  
<http://www.bsu.edu.eg/bsujournals/JVMR.aspx>  
Online ISSN: 2357-0520      Print ISSN: 2357-0512



## Original Research Article

# Ultrasonography of the mammary gland in ruminants

Ragab, G. H.<sup>a</sup>, Seif, M. M.<sup>a,\*</sup>, Qutp, M. M.<sup>b</sup>

<sup>a</sup> Department of Surgery, Anesthesiology and Radiology, Faculty of Veterinary Medicine, Beni-Suef University, Beni-Suef 62511, Egypt .

<sup>b</sup> Veterinarian in Garado Veterinary Unit, El- Fayoum, Egypt.

## ABSTRACT

Information regarding the use of ultrasonography in the diagnosis of udder and teat affections is scarce in ruminant. The present study was conducted on 30 cows, 20 ewes and 45 does. The surgical affections of udder and teats were recorded in 10 cows, 5 ewes and 15 does. In normal udder, glandular parenchyma on ultrasonographic examination appeared as homogenous and hyperechoic with anechoic alveoli, the milk appeared with high pitched anechoic large areas. While in the teat skin echoed strongly, the middle layer less echogenic than skin in a homogenous, uniform pattern and the teat canal represented by extending area between the two hyper-echoic lines forming anechoic lumen. In multiple abscesses, the glandular parenchyma of udder appeared as multiple hyper-echoic areas surrounded by hypo-echoic margin. In case of super numerary teats, presence of hypo-echoic to an-echoic areas separated by hyper-echoic septa due to each teat had separated milk cisternae. In case of complete teat obstruction, presence of hyper-echoic obstructive mass which present in teat canal. In conclusion, ultrasonography is a good tool for differential diagnosis of different udder and teat affections.

## ARTICLE INFO

### Article history:

Received .....

Accepted .....

Online .....

### Keywords:

ultrasonography,  
udder, teat,  
ruminant.

\* Corresponding author: Mohamed Seif; Department of Surgery, Anesthesiology and Radiology, Faculty of Veterinary Medicine, Beni-Suef University, Beni-Suef 6511, Egypt. Tel. and Fax. (+2) 0822327982. Email: [seif\\_th2003@yahoo.com](mailto:seif_th2003@yahoo.com)

## 1. Introduction

The quantity and quality of milk production is directly dependent on good healthy animals and its udder (Twardon et al., 2001).

Surgical affections of udder and teat are getting much attention nowadays because of its economic

importance to the farmer (Ramesh et al., 2005). Nowadays, ultrasonography is used extensively as a safe and non-invasive diagnostic tool in veterinary practice (Neijenhuis et al., 2001; Fricke, 2002).

Ultrasonography is a valuable technique for visualizing any changes of the cisternal and internal

structure of the mammary gland cistern to be observed clearly (Ayadi et al., 2003; Szencziová, and Strapák, 2012).

Shamaa (1999) and Franz et al. (2009) mentioned that mammography is a helpful tool to diagnose the surgical alterations of the udder such as inflammation, mucosal lesions, tissue proliferation, foreign bodies, milk stones, hematoma, and abscess.

So, the aims of this study are to through light on the importance of ultrasonogram as accurate and quick tool for diagnosis of udder and teat affections, in addition to study the normal ultrasonography of udder and teat.

## 2. Materials and methods

The present study had done at surgery, anesthesiology and radiology department, faculty of veterinary medicine, Beni-Suef University. Ultrasonography was conducted on 30 cows, 20 ewes and 45 does. Among such animals, 10 cows, 5 ewes and 15 does were having surgical affections. The animals were given tranquilizer (Xylazine Hcl 2%, 0.05-0.2 mg / kg) Xylaject® ADWIA /400kg body weight) before examination. Physical examination of the udder and teats was done according to Legard (1938). Ultrasonographic examination using B-mode linear multi -frequency probe (transducer) 5, 7.5 and 10 megahertz was done.

In cows, teats were examined by standoff or water cup technique using plastic bag containing warm water. Teats of ewes and does were viewed by water cup technique (Shamaa 1999; Franz et al., 2009).

## Results

### 3.1. Normal udder and teat

Ultrasonographic examination of the glandular parenchyma of the normal active lactating udder in cow appeared as homogenous and hyperechoic with anechoic alveoli. The milk appeared as high pitched anechoic large areas (Figs.1,2). In the teat skin echoed strongly, the middle layer less echogenic than skin in a homogenous, uniform pattern and the teat canal represented by extending area between the two hyper-echoic lines forming anechoic lumen (Figs.3,4).

In normal non-lactating udder of cows, all the duct system appeared very small anechoic areas representing the collapsed lactiferous duct system

(Figs.5,6). The teat appeared without the non-echoic lumen and the two inner layers appeared as one strongly echoic white line (Fig.7).

The difference between ultrasonographic picture of normal udder and teat in small and large ruminant was in the size of layers.

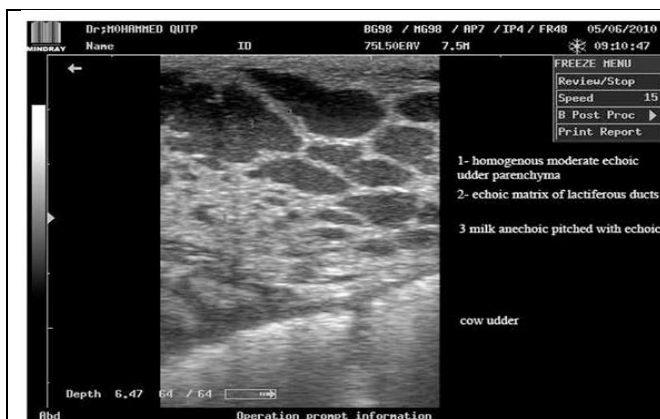### 3.2. Surgical affections of udder and teats

In does with multiple abscesses (Fig. 8), the glandular parenchyma of udder appeared as multiple hyper-echoic areas surrounded by hypo-echoic margin with homogenous echoic mammary tissue (Fig. 9).

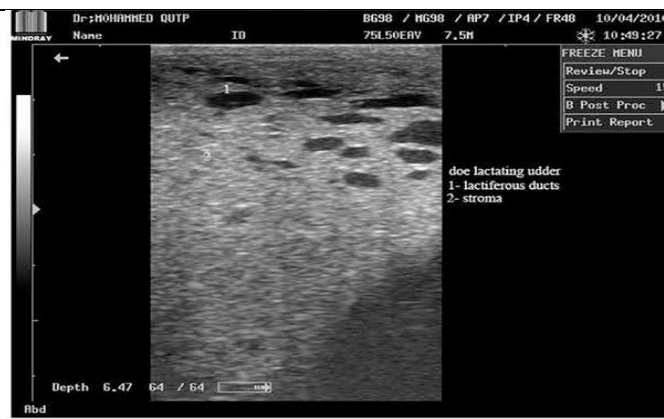
In cases of acute mastitis in cows (Fig. 10), a non-homogenous echogenicity and less visualized alveoli were appeared (Fig. 11). In cases of chronic mastitis in cows (Fig. 12), hyper-echoic rods (Fig. 13) were observed. In udder abscesses in cows (Fig. 14), the ultrasonographic picture showed that presence of hyper-echoic mass surrounded by less echoic area followed by hyper-echoic bands inside these mass present an-echoic dots (Fig. 15).

The results observed that, in case of udder haematoma (Fig. 16), the ultrasonographic picture showed the presence of moderate echoic patches of different sizes separated by hyper-echoic septa (Fig. 17). In cases of complete teat obstruction (Fig. 18), the ultrasonographic picture showed that presence of hyper-echoic obstructive mass which present in teat canal (Fig. 19).

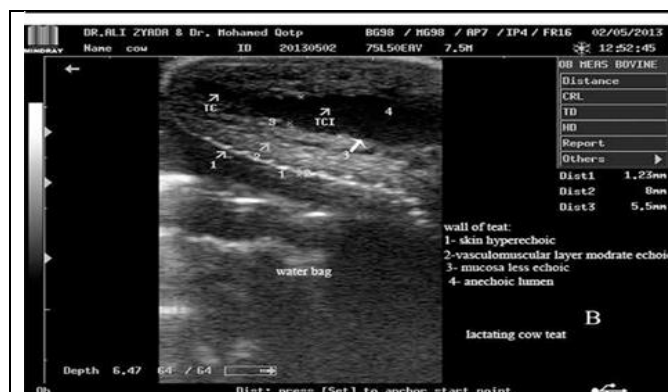In does with super numerary teat in connect with the milk cisternae (Fig. 20), the ultrasonographic picture showed that presence of hypo-echoic area surrounded by hyper-echoic border with incomplete hyper-echoic septum (Fig. 21). In does with super numerary teats (Fig. 22), the ultrasonographic picture exhibited the presence of hypo-echoic to an-echoic areas separated by hyper-echoic septa of the cisternae (Fig. 23).



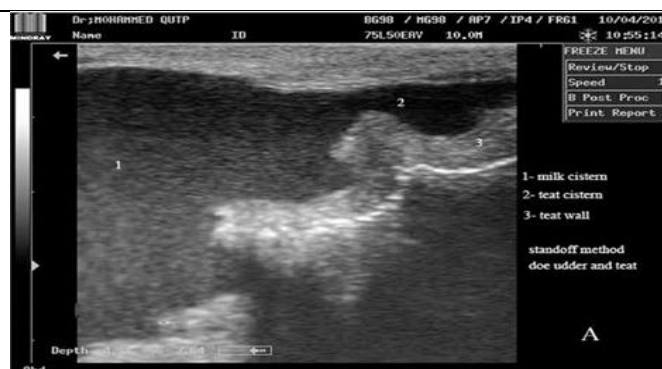**Fig.1.** Homogenous and hyperechoic with anechoic alveoli. The milk appeared with high pitched anechoic large areas in normal lactating udder ultrasonogram of cows.



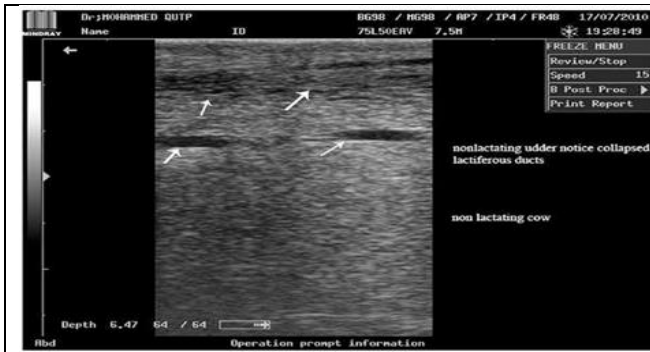**Fig. 2.** Homogenous and hyperechoic with anechoic alveoli in normal lactating udder of a doe.



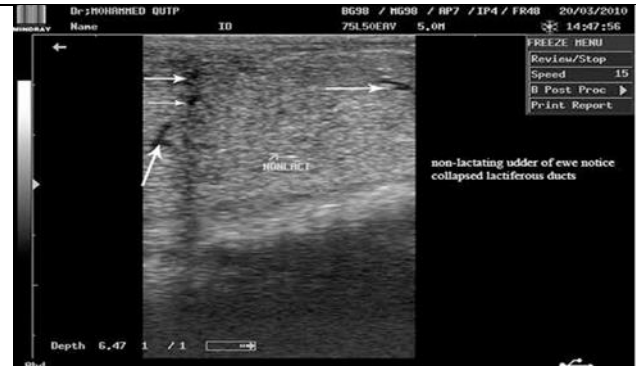
**Fig. 3.** Teat skin echoed strongly. The middle layer was less echogenic than skin. 1: Skin. 2:Vasculomuscular layer. 3: Mucosa. 4: Lumen. Tc: teat canal in normal teat of cow.



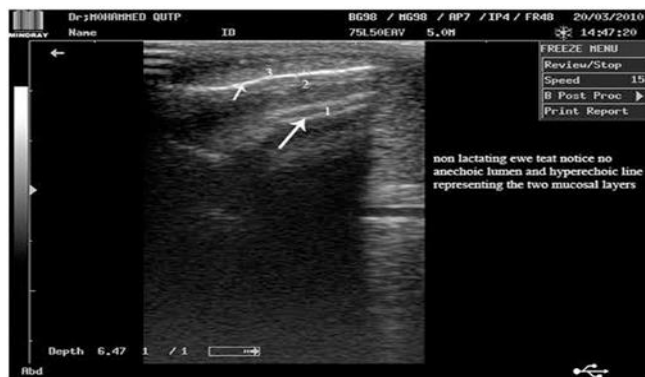**Fig. 4.** 1: Milk cistern, 2: Teat canal. 3: Teat wall in normal lactating teat of a doe.



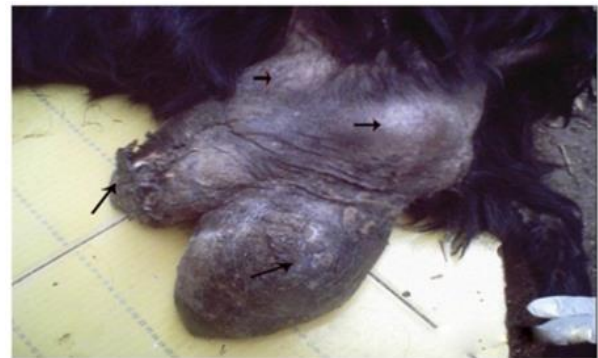**Fig.5.** All the duct system appeared very small anechoic areas representing the collapsed lactiferous duct system (White arrows) in normal non-lactating udder of cow.



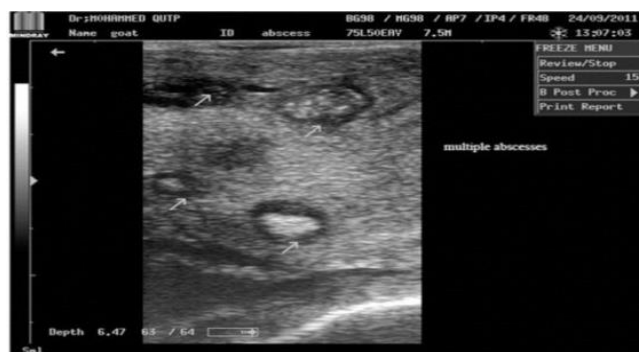**Fig.6.** All the duct system appeared very small anechoic areas representing the collapsed lactiferous duct system (White arrows) in normal non-lactating udder of ewe.



**Fig.7.** Normal non-lactating teat of ewe appeared without the non-echoic lumen and the two inner layers appeared as one strongly echoic white line (White arrows).



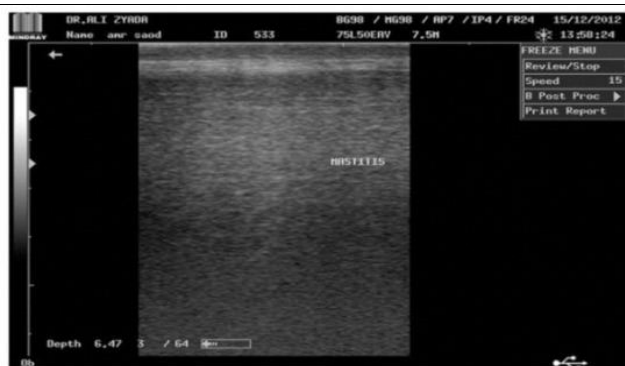**Fig. 8.** A doe with multiple Udder abscessation.



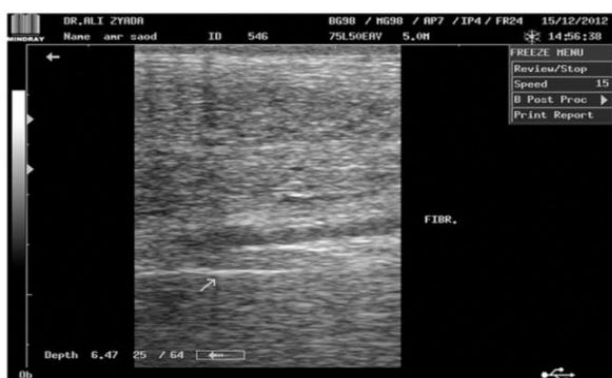**Fig.9.** Multiple hyper-echoic areas surrounded by hypo-echoic margin (white arrows), in a doe with udder abscesses.



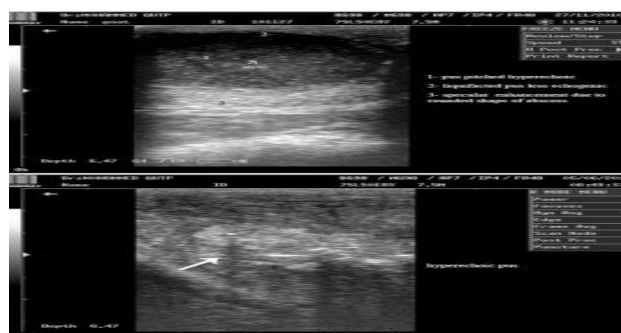
**Fig. 10.** Acute mastitis in a cow recovered from examined turkeys.



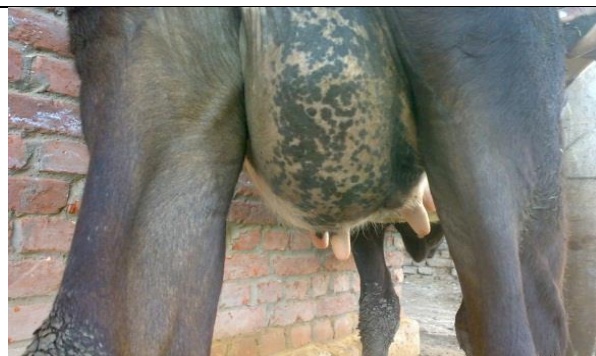**Fig.11.** Non-homogenous echogenicity and less visualized alveoli in acute mastitis of cow.



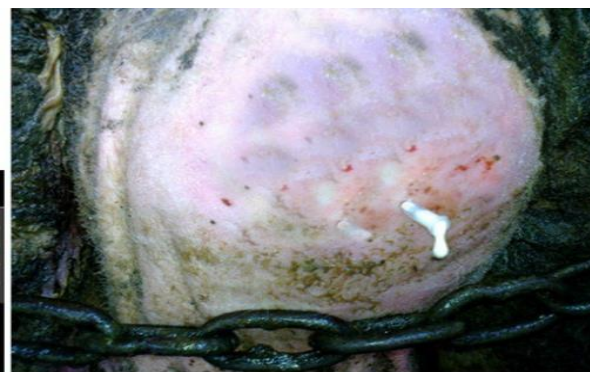**Fig.13.** Hyper-echoic rods (white arrow) in chronic mastitis of a cow.



**Fig.15.** Multiple hyper-echoic areas surrounded by hypo-echoic margin (white arrows), in a doe with udder abscesses.



**Fig.12.** Chronic mastitis in a cow.

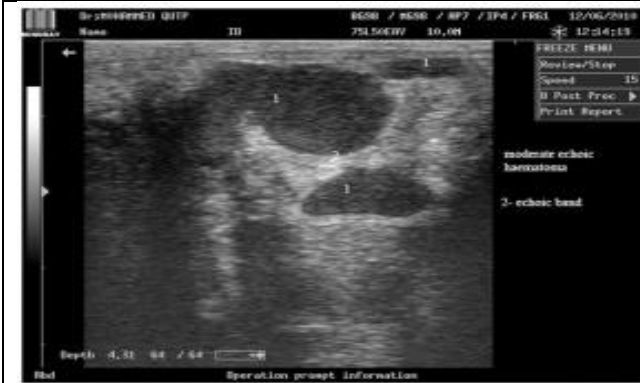

**Fig. 14.** An udder abscess with exploratory puncture of a cow.

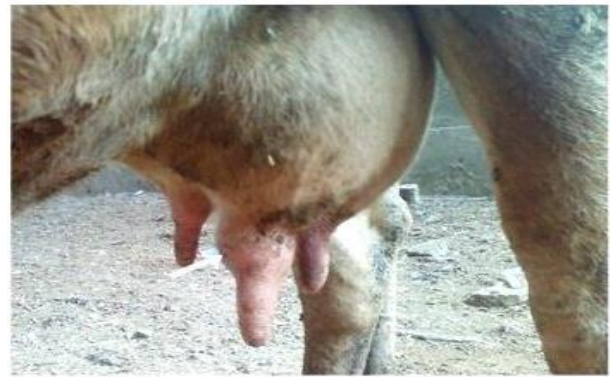

**Fig. 16.** Udder haematoma in a cow (red arrows).

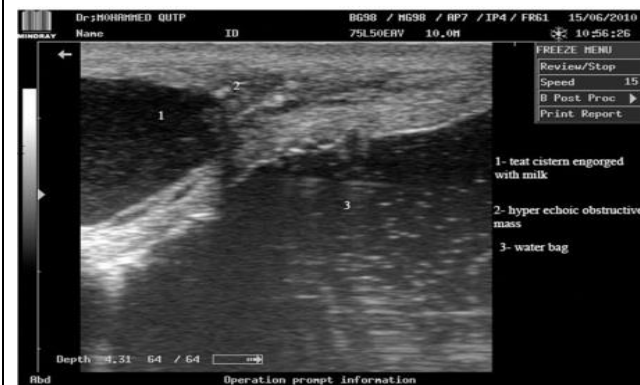



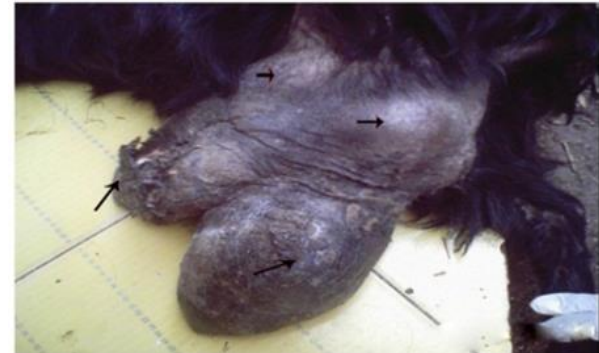**Fig.17. Moderate echoic patches of different sizes (1) separated by hyper-echoic septa (2) in a cow with udder haematoma.**



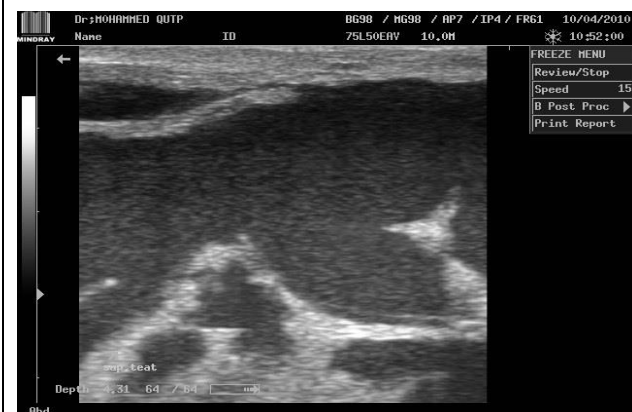**Fig.18. A complete teat obstruction in a cow.**



**Fig.19. Hyper-echoic obstructive mass (2) in teat canal (1) and water bag (3) in a cow with a complete teat obstruction.**



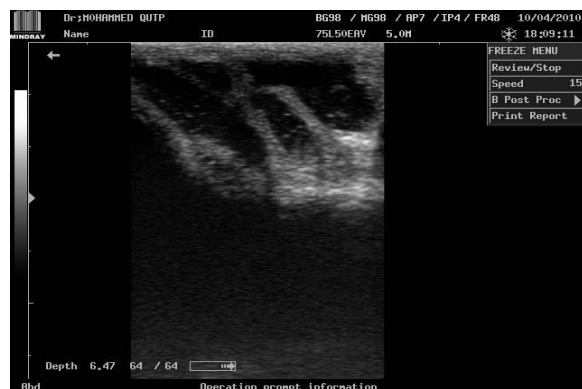**Fig. 20. A super numerary teat in a doe.**



**Fig.21. A super numerary teat ultrasonogram in a doe showing hypo-echoic area surrounded by hyper-echoic border with incomplete hyper-echoic septum and presence of two milk cisternae.**



**Fig. 22. Super numerary teats in a doe.**



**Fig. 23. Multiple hyper-echoic areas surrounded by hypo-echoic margin (white arrows) in a doe with udder abscesses.**

#### 4. Discussion

The usage of modern, accurate and relatively quick methods for udder examination like ultrasonography are necessary for regard udder illnesses and health problems, due to their negative impact on the milk production and economics of herds (Szencziová and Strapák, 2012). The use of proper and most common B-mode ultrasonography equipment allows the differentiation of morphological structures, such as mammary gland parenchyma, gland and teat cisterns, teat wall, rosette of Furstenberg, and teat canal (Franz et al., 2001).

In the sonographic image, the teat wall appears as a threefold layered structure. The teat skin appears as a 1–2 mm thin, bright, echoic line and is followed by the muscular/connective tissue layer containing blood vessels showing a thicker, homogeneous, less echoic layer with inclusion of anechoic cavities. The internal boundary as mucous membrane appears as a thin bright line (Hospes and Seeh, 1999; Franz et al., 2001).

The lining of wall of the gland sinus appears as mixed hyper-hypothetic folds. The lactiferous ducts are anechoic areas within the hypothetic matrix of the fold. Gungor et al. (2005) described the lactiferous duct as elongating anechoic branches in hyper-echoic mammary parenchyma. Some of the anechoic areas within the glandular parenchyma may have been blood vessels but others certainly were lactiferous ducts, because they could be seen entering the gland sinus.

In the non-lactating udder, all the duct system appeared very small anechoic areas representing the collapsed lactiferous duct system, while the teat appeared without the non-echoic lumen and the two inner layers appeared as one strongly echoic white line this picture supported by that's described by Shamaa (1999), Abshenas et al. (2007) and Rambabu et al. (2008).

Ultrasonographic picture of abscess characterized by central less echoic area patched with high echoic dots and surrounded by echoic narrow area representing the biogenic membrane in agree with the finding of Flock and Winter (2006) who observed abscess as round well-defined structures of varying size with a distinct capsule and hypoechoic area.

Regarding to udder chronic mastitis had hyperechoic cordial bands representing the fibrous tissues which replace the glandular tissues. Such finding agreed with those obtained by Rambabu (2008).

The teat obstruction occurs at different levels, either at the base of teat due to chronic inflammation of the annular fold, at the teat canal due to milk calculi, polyps, and fibrosis of the teat canal or at the tip of the teat, due to scratch and scab formation. Also it may be complete or incomplete obstruction (Abd-Elhady, 1993; John et al., 1998).

In the present study, ultrasonography facilitated diagnosis and proving of obstruction nature as obstructing masses appeared hyper-echogenic in non-echogenic streak canal or teat cistern. Those results agreed with those given by Hoque et al. (2004), Nak et al. (2005) and Rambabu et al. (2008).

The application of water bath method for teat ultrasonography increases the acoustic impedance difference between the teat wall and the surrounding medium. This is in coincidence with previous literature (Rambabu, 2008; Szencziová and Strapák, 2012).

For ultrasonographic visualization of the structures of the bovine teats, linear probes with a frequency of 3.5–10 MHz are used; this is in agreement with (Hospes and Seeh, 1999). The normal appearance of the udder and teat are amenable to sonographic imaging because of their superficial location and the technique has the potential to diagnose different conditions of the organ. Rambabu et al. (2008) reported that the glandular parenchyma of udder on ultrasonographic examination appeared as homogenous and

hyperechoic with anechoic alveoli, which was in accordance with Ayadi et al. (2003) in cows.

The current study showed that ultrasonography used for the examination of the mammary gland parenchyma in inflammatory processes (mastitis), pathological formations localized deep within the parenchyma (abscesses, haematomas, connective tissue buildups), which cannot be detected by clinical examination (Flock and Winter, 2006; Franz et al., 2009).

## 5. Conclusion

Ultrasonography is a useful tool for differential diagnosis of different udder and teat affections in ruminants.

## References

- Abd El-hady A, Azab A (1993). Studies on the prevalent surgical udder and teat affection in dairy farms. Thesis, M.V.Sc., Cairo University, Egypt, pp. 63–145.
- Abshenas J, Vosough D, Masoudifard M, Molai M.M (2007). B-mode ultrasonography of the udder and teat in she-camel (*She-camelus dromedarius*) University of Tehran, Tehran - Iran. J. Vet. Res., 62 (2): 27–31.
- Ayadi M, Caja G, Such X, Knight CH (2003). Use of ultrasonography to estimate cistern size and milk storage at different milking intervals in the udder of dairy cows. J. Dairy Res., 70(1):1–7.
- Flock M, Winter P (2006). Diagnostic ultrasonography in cattle with diseases of the mammary gland. Vet. J., 171(2): 314–321.
- Franz S, Floek M, Hofmann-Parisot M (2009). Ultrasonography of the bovine udder and teat. Vet. Clin. North Am. Food Anim. Pract. 25 (3): 669–685.
- Franz S, Hofman-Parisot W, Windischbauer G, Suchy A, Bauder B (2001). Ultrasonography of the teat canal in cows and ewes. Vet. Rec., 149(4): 109–112.
- Fricke PM (2002). Scanning the Future- Ultrasonography as a reproductive management tool for dairy cattle. J. Dairy Sci., 85(8): 1918–1926.
- Hospes R, Seeh C (1999). Sonographie. In: Sonographie und Endoskopie an der Aitze des Rindes, Schattauer, Stuttgart, p. 29–48.
- Hoque M, Jiuary R, Maiti SK, Singh GR, Gupta OP, Kumar N (2004). Ultrasonography of bovine udder and teat. Abstract 11th Annual Congress of Indian Association for Advancement of Veterinary Research (IAAVR), IVRIJzatnagar.
- John H, Hässig M, Gobet D, Sicher D, Jaeger P (1998). Clinic of Urology, Kantonsspital Winterthur, Zürich, Switzerland. Br J Urol. 82(6):906–909
- Gungor O, Pancarci SM, karaBacak A (2005). Examination of equine udder and teat by B-mode ultrasonography. Kafkas Üniv. Vet. Fak. Derg., 11:107–111.
- Legard HM (1938). Clinical examination of bovine udder. Can. J. Comp. Med., 2(4): 111–112.
- Nak D, Nak Y, Keskin A (2005) Diagnosis of various teat lesions in dairy cows by ultrasonography. Indian Vet. J., 82(11): 1163–1166.
- Neijenhuis F, Klungel GH, Hogeveen H (2001). Recovery of cow teats after milking as determined by ultrasonographic scanning. J. Dairy. 84(12):2599–2606.
- Rambabu K, Makkena S, Suresh Kumar RV, Rao TSC (2011). Incidence of udder and teat affections in buffaloes. Tamilnadu J. Vet. Anim. Sci., 7 (6):309–311.
- Ramesh T, Hoque M, Kumar B, Prabhakar K (2005). Surgical condition of udder and teats in cows. Ind Cow 6(5): 25–27.
- Rambabu K, Makkena S, Suresh RV, Kumar R, Rao TS (2008). Ultrasonography of the udder and teat in buffaloes: A comparison of four methods. Buffalo Bull., 27(4): 269–273.
- Shamaa AA (1999). Ultrasonic mammography in goats. Proc. 24th Arab. Vet Med. Cong. (J. Egypt Vet. Med Ass. 59 (2&3): 735–755.
- Szencziová I, Strapák P (2012). Ultrasonography of the udder and teat in cattle: perspective measuring technique. Slovak J. Anim. Sci., 45 (3): 96–104.
- Twardon J, Dziecio M, Nizamski M, Dejneka G J (2001). Use of ultrasonography in diagnosis of teats disorders. Med. Vet., 57 (12), 874–875.