



Journal homepage:
<http://www.bsu.edu.eg/bsujournals/JVMR.aspx>
Online ISSN: 2357-0520 Print ISSN: 2357-0512



Case Report

A case report of lobar agenesis in the lung of a sheep and extra lobation in the lungs of dogs in Trinidad

Mohamed, R.^{1, 2 *} Georges, K.¹, Rajh, S.¹ and Suepaul, R.¹

¹Department of Basic Veterinary Sciences, School of Veterinary Medicine, Faculty of Medical Sciences, The University of the West Indies, St. Augustine, Republic of Trinidad and Tobago.

²Department of Anatomy and Embryology, Faculty of Veterinary Medicine, Beni- Suef University, Beni Suf 62511, Egypt.

ABSTRACT

A clear understanding of the pulmonary morphology of domestic animals is essential for the recognition and investigation of any anatomical variations. The right and left lungs of small ruminants and dog are separated into distinct lobes by inter lobar fissures. The right lung in these animals typically divides into 5 and 4 lobes, respectively. However, the left lung divides into 3 lobes. We report a case of congenital absence of the middle lobe of the right lung of a sheep and extra lobation in the left lungs of two dogs in Trinidad. This case report is of value to veterinary radiologists, pathologists, and veterinary public health inspectors during examination and investigation of the thoracic cavity of the sheep and dog.

ARTICLE INFO

Article history:

Received

11/9/2019

Accepted

10/12/2019

Online 1/2/2020

Keywords:

Abnormalities,
Dog, Lung, Sheep,
Trinidad

Corresponding author: Mohamed, R. ^{1, 2 *}, ¹Department of Basic Veterinary Sciences, School of Veterinary Medicine, Faculty of Medical Sciences, The University of the West Indies, St. Augustine, Republic of Trinidad and Tobago.

²Department of Anatomy and Embryology, Faculty of Veterinary Medicine, Beni-Suef University, Beni Suf 62511, Egypt.

Email: kkidareda@gmail.com

1. Introduction

Mammalian lungs are paired asymmetrical organs occupying the thoracic cavity, functioning as the interface for gaseous exchange (Frandsen et al., 2009). Congenital pulmonary malformations are rare, except in cattle and sheep. (McGavin and Zachary, 2011). Anomalies such as the underdevelopment of the lung parenchyma, bronchial tree, and pulmonary artery are classified as hypoplasia, aplasia or agenesis (Gupta et al., 2017). Defects have not been widely reported in the literature except the abnormal lobulation in the right lung of a dog (Arican et al., 2011). This case report is of great value to the veterinary profession as it would assist in the thorough understanding of the lung abnormalities during gross and clinical evaluation.

2. Material and methods

Specimens were obtained from a study investigating the effects of air pollution on the pulmonary morphology of both small ruminants and dogs. A total of 100 fresh lungs of apparently healthy adult small ruminants, were collected from different locations in Trinidad and Tobago. Fifty lungs of dogs were obtained after euthanasia by the local humane society. Specimen analyses were conducted by personnel of the Anatomy Laboratory of the School of

Veterinary Medicine (SVM). Lobation of the lungs of sheep and dogs were recorded. Gross photographs were taken for the dorsal and ventral aspects of the lungs using a digital camera. Ethical approval from CEC/UWI, St. Augustine (CEC 181/04/17) was obtained.

3. Results

The normal lobation patterns of the lungs were found in 99% and 96% of lungs of domestic sheep and mixed breed dogs respectively as the right lungs of sheep and dog consisted of apical, middle, accessory and diaphragmatic lobes, while the left lungs consisted of apical (cranial and caudal) and diaphragmatic lobe. In sheep, the right apical lobe has cranial and caudal parts (Fig. 1).

The right middle lobe of the right lung of one male sheep was not detected (Fig. 2 E & F). Two mixed breed male dogs presented lung abnormalities; one showed extra lobation in the left lung (Fig. 2 G & H), while the right cranial lobe of the right lung of the second case showed lobation by an accessory fissure into a cranial and a caudal apical lobe (Fig. 2 I & J).

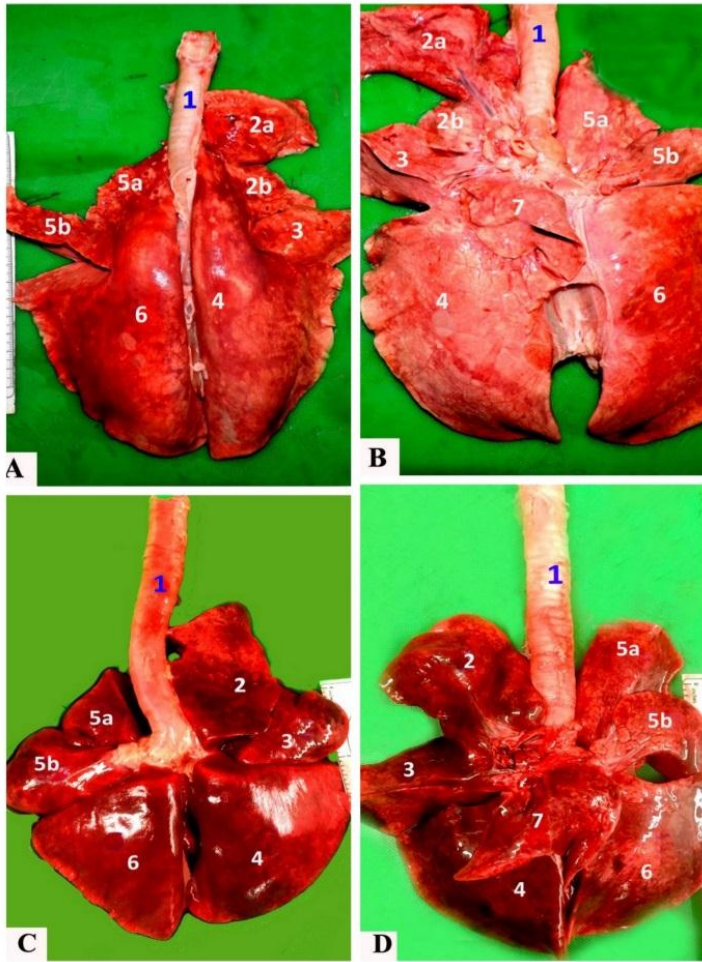


Fig.1 Photographs showing the dorsal and ventral aspects of the normal lungs of a sheep (A&B) and a dog (C&D)

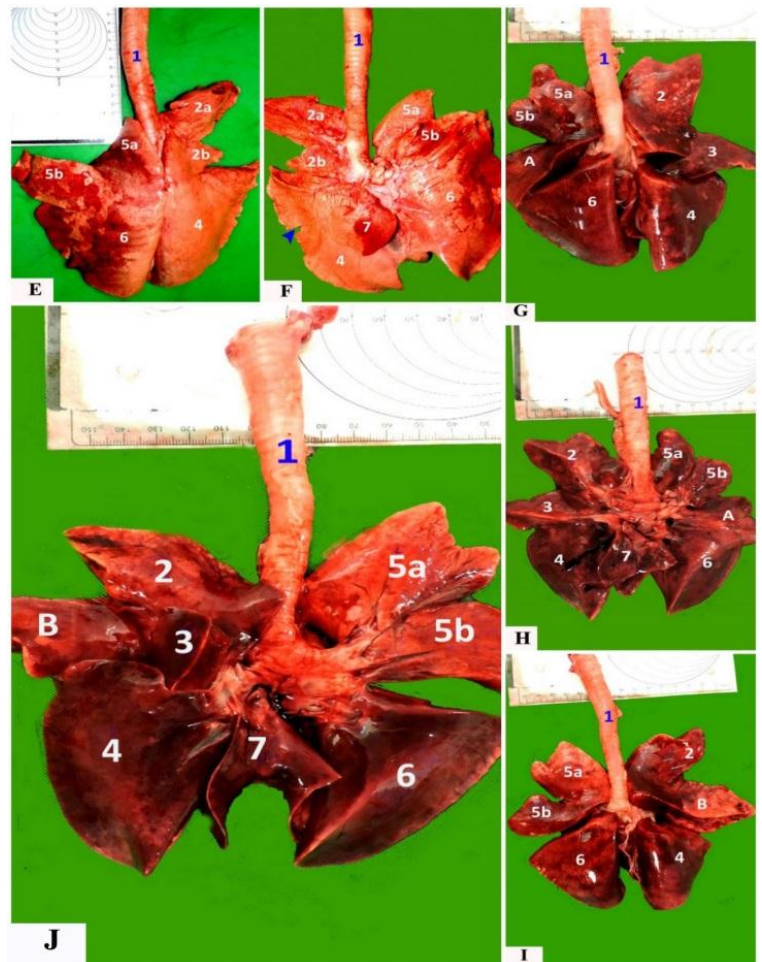


Fig.2 Photographs showing the dorsal and ventral aspects of the abnormal lungs of a sheep (E&F) and dogs (G, H, I & J)

1- Trachea; 2a-Cranial part of the cranial lobe of the right lung; 2b- Caudal part of the cranial lobe of the right lung; 3- Middle lobe of the right lung; 4- Diaphragmatic lobe of the right lung; 5a- Cranial part of the cranial lobe of the left lung; 5b- Caudal part of the cranial lobe of the right lung; 6- Diaphragmatic lobe of the left lung; 7- Accessory lobe of the right lung.; A- Abnormal extra lobation of the left of a dog; B- Abnormal lobation of the cranial lobe of the right lung; Blue arrowhead-The possible fusion of the middle and the diaphragmatic lobes of the right lung.

4. Discussion

The morphological differentiation of the lungs of various domestic animal species is based on the extent of lobation and lobulation. Abnormal lung lobation as observed in this case study may prove difficult for an investigator to identify the species, based on gross characteristics.

The left lung of all species consists of two lobes; cranial and caudal where the cranial lobe is further divided into cranial and caudal parts. In most domestic animals including the dog, the right lung consists of four lobes which are the cranial, caudal, middle and accessory lobes. The lungs of sheep include an additional lobe as the cranial lobe is further divided into cranial and caudal parts (Konig et al., 2007 and Dyce et al., 2010).

The pulmonary morphology of the animals examined in this case report was distinctly different from its typical gross structure. These findings may indicate a genetic abnormality during embryogenesis, namely foregut development (Voyevoda et al., 1992). Additionally, the absence of the middle lobe of the right lung of sheep could be attributed to another embryonic defect such as fusion of the middle and diaphragmatic lobes, which to date have not been recorded in the presently available literature.

All the animals in this study were apparently healthy adults. Cases reports of anatomical abnormalities are of significance for veterinary diagnostic imaging specialists, veterinary pathologists, and Veterinary public health inspectors.

5. Conclusion

This case report is of value to veterinary surgeons, radiologists, pathologists, and veterinary public health inspectors during examination and investigation of the thoracic cavity of sheep and dogs.

6. Acknowledgments

The authors acknowledge the expert technical assistance of Basic Veterinary Sciences, School of Veterinary Medicine, Faculty of Medical Sciences, The University of the West Indies, St. Augustine, Trinidad and Tobago.

References

- Arican I, Serbest A, Yilmaz B (2011). Abnormal lobulation in a dog's right lung. *Journal of Animal and Veterinary Advances*, 10 (17): 2253-2255.
- Dyce KM, Sack WO, Wensing CJG (2010). *Text Book of Veterinary Anatomy*. 4th ed. W. B. Saunders Co., Philadelphia, London, Toronto, Montreal, Sydney, Tokyo. pp 670-671.
- Frandsen RD, Wilke WL, Fails AD (2009). *Anatomy and physiology of farm animals*. 7th ed. Wiley Blackwell, Iowa; USA. pp 317-334.
- Gupta K, Taneja D, Aggarwal M, Gupta R (2017). Left upper lobar agenesis of lung: A rare case report. *Lung India*, 34: 302-4.
- McGavin MD, Zachary JF (2011). *Pathologic basis of veterinary disease*. 4th ed. St. Louis: Mosby Elsevier. P 493.
- Konig HE, Liebich HG, Bragulla H (2007). *Veterinary anatomy of domestic mammals: Textbook and colour Atlas*. 3rd ed. Schattauer Verlag. pp 358-364.
- Voyevoda TV, Shishkin. GS, Valitskaya RI, Umantesva ND (1992). Macrostructure differences of polar fox and dog lungs. *Anat Rec.*, 234 (1): 89-92.